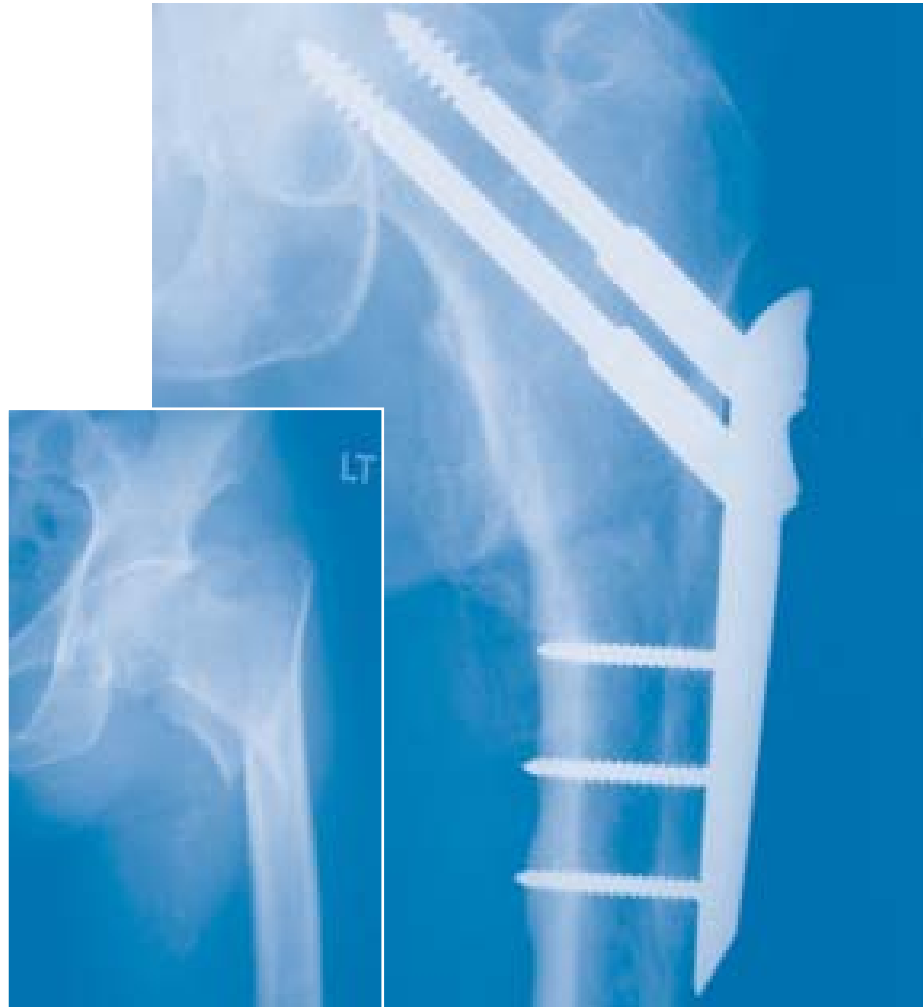



The Gotfried PC.C.P

for Percutaneous Compression Plating
of Pertrochanteric Hip Fractures

By Dr. Y. Gotfried MD.M.S.

	Page N°
INTRODUCTION	1
REFERENCES	2
EQUIPMENT REQUIRED	3
CLEANING AND STERILIZATION	6
OPERATIVE TECHNIQUE	7
POST-OPERATIVE MANAGEMENT	24

Percutaneous Compression Plating was developed by considering each of the stages in the surgical procedure for pertrochanteric fractures and the ways in which these might be improved. Primary objectives were that there should be minimal operative trauma and blood loss in patients whose general condition is frequently compromised by severe concomitant medical or surgical conditions, and that walking ability should be maintained. Its use in both stable and unstable pertrochanteric hip fractures has resulted in improved outcomes^{1,2,3}. This new system represents a minimally invasive method of fracture stabilization and fixation, providing enhanced rotational stability⁴ and bone sparing⁶. The technique reduces both operative and post-operative complications including “cut outs” and fracture collapse^{1,2}. A statistically significant reduction in post-operative pain has been recorded³. Weightbearing may be permitted immediately post-operatively.

The PC.C.P technique is designed around four fundamental principles:

1. Closed Fracture Reduction to a 135° shaft/neck angle
2. Minimally Invasive Surgery with no Exposure of the Fracture
3. The Provision of Rotational Stability
4. Prevention of lateral wall fracture and hence of fracture Collapse

Closed Fracture Reduction:

Posterior fracture sagging must be reduced and reduction maintained until fixation is complete. Use of the posterior reduction device (PORD™ device) facilitates this procedure and is therefore an integral feature of the Percutaneous Compression Plating technique¹.

In the past, the plate-screw or nail-screw angle of a fixation device has been chosen according to the shaft / neck angle achieved during fracture reduction. Plates have classically been produced with a range of different angles. Since, however, a shaft / neck angle of 135° has been shown to be superior, biomechanically, for both fracture impaction and fixation device sliding^{7,8}, it follows that this is the angle to which the fracture should be reduced, thereby optimizing impaction, and hence, fracture healing. The PC.C.P technique ensures that this angle is achieved.

Minimally Invasive Surgery with no Exposure of the Fracture:

Minimally invasive surgical techniques have proven successful in reducing operative complications and post-operative morbidity⁹. This is particularly relevant in relation to pertrochanteric hip fractures. The present technique was specifically designed with this requirement in mind.

Provision of Rotational Stability:

Single-axis fixation provides poor control of rotational stability¹⁰. The PC.C.P provides double-axis telescoping fixation, which also increases the projection area within the femoral head. Biomechanical studies with the PC.C.P have revealed a significant increase in rotational stability which is critical for providing “controlled fracture impaction”⁴. This is the post-surgical compression, passively exerted by the patient, and is provided by a fixation device which has a sliding capability, as well as rotational stability. Rotational instability has been reported to cause irreversible caudal shift and varus tilt of the femoral head¹¹, which may result in femoral head “cut out”, a frequently reported complication of intertrochanteric fracture fixation^{12,13,14}.

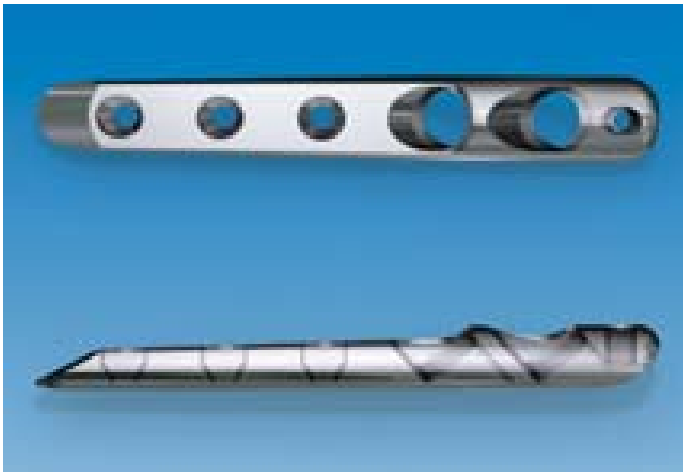
That this complication is not associated with PC.C.P fixation has been attributed to the improved rotational stability provided by the double axis telescoping mechanism.

Prevention of Collapse:

Traditionally, the medial and postero-medial fracture fragments have been considered to be the most important elements in determining the severity of the pertrochanteric hip fracture. This is certainly true, but only in assessing the extent of the bony damage. The trochanteric portion which is not broken, and which remains for fracture reconstruction, namely the lateral wall is, however, no less important. This portion provides the best opportunity for osteosynthesis with the proximal part of the fracture complex, since it is the proximal extension of the femoral shaft. In an unstable three or four part pertrochanteric fracture, the lateral wall is very fragile and fracture of this delicate structure will convert an pertrochanteric fracture into what is effectively a subtrochanteric fracture, which is a more severe problem and should be avoided at all costs⁵. An intact lateral wall, therefore, plays a key role in the stabilization and fixation of unstable pertrochanteric fractures. By providing a lateral buttress for the proximal fragment, fracture impaction is facilitated, and followed by rotational and varus stability once fracture spike impaction occurs. If the lateral wall is broken, there is no lateral buttress for the proximal neck fragment and collapse will follow^{5,6}. This has been reported to be a major contributor to post-operative morbidity^{15,16} as it is followed by a long period of disability.

No lateral wall damage and no fracture collapse have been reported with use of the PC.C.P¹². This is attributed to the small diameter of the holes at the drilling site with PC.C.P following incremental drilling from 7 to 9.3 mm, compared with the 16-32 mm drilling required for the screw barrel of the dynamic/compression hip screw.

1. **Gotfried Y.** Percutaneous compression plating of intertrochanteric hip fractures. *J Orthop Trauma* 2000; 14: 490-5
2. **Krasheninnikoff M, Gramkow J, Tørholm C.** Gotfried PC. CP: a new method for osteosynthesis of intertrochanteric fractures of the femur. *Acta Orthop Scand* 1998; 280 (suppl): 30-1
3. **Janzing HM, Houben BJ, Brandt SE et al.** The Gotfried Percutaneous Compression Plate versus the Dynamic Hip Screw in the treatment of pertrochanteric hip fractures: minimal invasive treatment reduces operative time and postoperative pain. *J Trauma* 2002; 52: 293-8
4. **Gotfried Y, Cohen B, Rotem A.** Biomechanical Evaluation of the Percutaneous Compression Plating System for Hip Fractures. *J Orthop Trauma* 2002; 16: 644-50
5. **Gotfried Y.** Pantrochanteric Hip Fractures: An Entity. *J Bone Joint Surg [Br]* 2000; 82-B: Suppl III: 235
6. **Gotfried Y.** Percutaneous Compression Plating for Intertrochanteric Hip Fractures: Treatment Rationale. *Orthopaedics* 2002; 25: 647-52
7. **Meislin RJ, Zucherman JD, Kummer FJ, Frankel VH.** A biomechanical analysis of the sliding hip screw: the question of plate angle. *J Orthop Trauma* 1990; 4: 130-6
8. **Koval KJ, Zucherman JD.** Hip fractures II: evaluation and treatment of intertrochanteric fractures. *J Am Acad Orthop Surg* 1994; 2: 150-6
9. **Meinero M, Melotti G, Mouret PH.** *Laparoscopic Surgery.* Milan, Italy: Masson; 1994
10. **Swiontkowski MF, Harrington RM, Keller TS, Van Patten PK.** Torsion and bending analysis of internal fixation techniques for femoral neck fractures: the role of implant design and bone density. *J Orthop Res* 1987; 5: 433-44
11. **Claes L, Becker C, Simancher M, Hoellen I.** Improvement in the primary stability of the dynamic hip screw osteosynthesis in unstable, pertrochanteric fractures of osteoporotic bones by a new glass ionomer cement [German] *Unfallchirurg* 1995; 98: 111-23
12. **Adams CI, Robinson CM, Court-Brown CM, McQueen MM.** Prospective randomized controlled trial of an intramedullary nail versus dynamic screw and plate of intertrochanteric fracture of the femur. *J Orthop Trauma* 2001; 15: 394-400
13. **Parker MJ.** Cutting-out of the dynamic hip screw related to its position. *J Bone Joint Surg [Br]* 1992; 74B: 625
14. **Davis TR, Sher JL, Horsman A, Simpson M, Porter BB, Checketts RG.** Intertrochanteric femoral fractures. Mechanical failure after internal fixation. *J Bone Joint Surg [Br]* 1990; 72B: 26-31
15. **Bendo JA, Weiner LS, Strauss E, Yang E.** Collapse of intertrochanteric fractures fixed with sliding screws. *Orthopaedic Review* 1994; 30-7
16. **Stappaerts KH, Deldycke J, Broos PL, Staes FF, Rommens PH, Claes P.** Treatment of unstable peritrochanteric fractures in elderly patients with a compression hip screw or with the Vandeputte (VDP) endoprosthesis: a prospective randomized study. *J Orthop Trauma* 1995; 9: 292-7



Gotfried PC.C.P Plate 181000

This is of one size only; the head will be connected to the introducer, while the chisel-like end will pass through the tissues and on the surface of the periosteum. There are two oblique holes at the head for the femoral neck screws, and three more distal holes for the shaft screws.



Gotfried PC.C.P Neck Screws

Two are used with each plate; available lengths vary from 90 mm to 140 mm in 10 mm increments. Screws are telescopic with a barrel portion (a) which is screwed into the plate, and a self-tapping screw portion. The latter has a hexagonal recess (b), for the neck Screwdriver to advance the screw into the femoral neck. It also has an additional recess (c) which accepts the threaded part of the neck Screwdriver for drawing the screw (and with it the proximal fragment) backwards for fracture compression.

- 182090 Total length 90 mm
- 182100 Total length 100 mm
- 182110 Total length 110 mm
- 182120 Total length 120 mm
- 182130 Total length 130 mm
- 182140 Total length 140 mm



Gotfried PC.C.P Shaft Screws

These are self-tapping screws ranging in length from 31 mm to 43 mm in 3 mm increments. A threaded recess and two grooves at the screw head are used to attach the screws to the shaft Screwdriver.

- 183031 Total length 31 mm
- 183034 Total length 34 mm
- 183037 Total length 37 mm
- 183040 Total length 40 mm
- 183043 Total length 43 mm
- 183046 Total length 46 mm

Gotfried PC.C.P Instrument Tray Kit

PartNo.	Description	Quant.
180000	Gotfried PC.C.P instrument set complete, consisting of:	1
184000	Neck Screwdriver	1
185000Q	Shaft Screwdriver	1
186000Q	7.0 mm Drill Bit	1
187000Q	9.3 mm Drill Bit	1
188000Q	Shaft Step Drill	2
189000Q	Main Guide	1
190000	Quick Coupler	1
191000	Introducer	1
192000	Butterfly Screw	1
193000Q	Butterfly Pin	1
194000	Bolt	2
195000	Main Sleeve	1
196000	Neck First Sleeve	1
197000	Neck Second Sleeve	1
198000	Trocar - Neck	1
199000	Gauge Aluminium	1
200000	Impactor	1
201200	Aiming Guide	1
202000	Bone Hook Adapter	1
203000	Shaft Sleeve	1
204000Q	Trocar - Shaft	1
205000	Depth Gauge	1
206000	Skin Retractor	1
207000	Bone Hook	1
208000	Fixation Wire	1
209000	PC.C.P Instrument Case empty	1
210000	PC.C.P Template	1

Supplementary Equipment

- ⊕ PORD™ Device 110000
- No. 10 Scalpel Blade
- 18 Gauge Spinal Needle
- Metzenbaum scissors
- Mallet

⊕ Denotes available from Orthofix

210000 PC.C.P Template




190000 Quick Coupler




EQUIPMENT REQUIRED

Gotfried PC.C.P Instrument Case



Upper Tray



Lower Tray

Cleaning

Cleaning should be performed immediately after each procedure, before blood, saline and debris are dry.

Rinse with running hot water or immerse and agitate in a mild detergent bath with near neutral pH (7.0 to 8.0) and, whenever possible, distilled or demineralized water.

Avoid the use of abrasive pads. Ultrasonic cleaning in a hot detergent bath with the same pH limits will provide the most efficient cleaning. After cleaning rinse and dry the instruments for storage. The Neck Screwdriver and bone hook **MUST** be taken apart to insure adequate cleaning of all parts.

Lubrication by dipping in a water - soluble antimicrobial lubricant will help protect instruments against staining and corrosion. Follow lubricant manufacturer's instructions. These lubricants will not affect the sterilization process.

After cleaning, disinfection may be performed by immersion in a disinfectant solution such as Activated Glutaraldehyde (CIDEX) followed by rinsing and drying.

N.B.: As disinfection alone is not adequate, instruments should be sterilized before each procedure.

Sterilization

Prior to surgical use, the Instruments, Plates and Screws should be cleaned as described above and sterilized by a validated method in accordance with the sterilizer manufacturer recommendations and AAMI and ISO guidelines.


Recommended validated parameters:

Unwrapped "Flash" Gravity-Displacement Steam Sterilization

- Sterilizer type: Gravity
- Minimum temperature: 132° C
- Full cycle time: 20 minutes
- Minimum dry time: 0 minutes
- Instrument configuration: Unwrapped


Prevacuum Steam Sterilization

- Sterilizer type: Prevacuum
- Preconditioning pulses: 3
- Minimum temperature: 134° C
- Full cycle time: 3 minutes
- Minimum dry time: 0 minutes
- Instrument configuration: Individually wrapped



Fracture Reduction in the Frontal Plane

The patient is placed on a fracture table, and initial reduction obtained by traction under image intensification.



With the image of the proximal portion of the femur on the screen, the plastic template (210000) with a picture of the device in situ, is placed over it. Traction is then adjusted if necessary, to arrive at a neck-shaft angle of 135 degrees and to ensure that the more distal neck screw will lie 2-3 mm above the femoral calcar.

The arrow on the template indicates the position at which a spinal needle will shortly be inserted to define the position of the first skin incision.



Posterior Reduction of the Fracture

Any posterior sagging at the fracture site should now be corrected and maintained using the dedicated Posterior Reduction (PORD™) Device. This device is easily attached to most fracture tables.

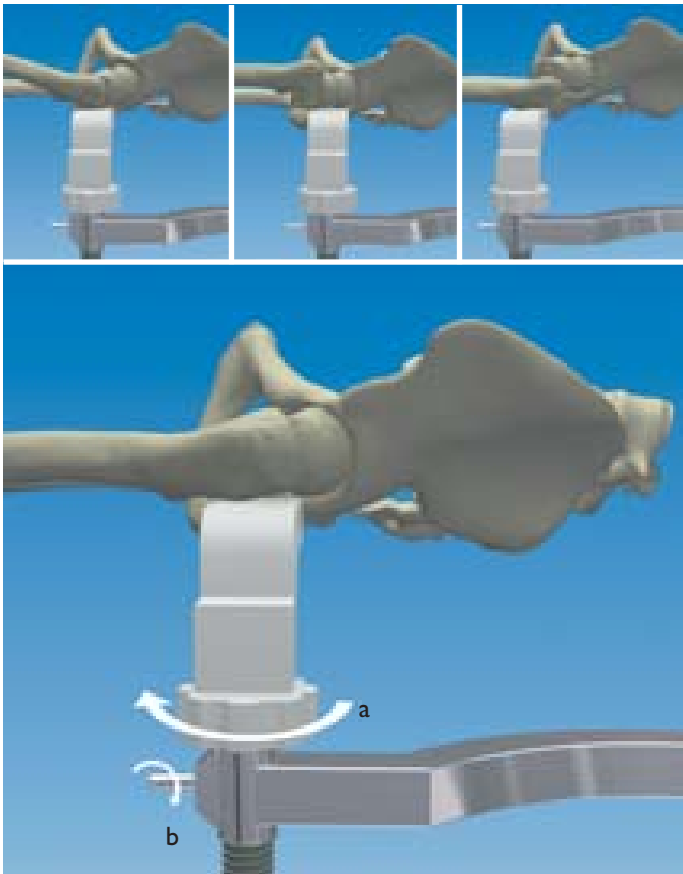
Position the patient on the fracture table.
Slide the Clark Attachment on to the side rail of the fracture table. Insert the vertical post of the Box Bracket into the Clark Attachment from beneath and tighten the clamp on the post so that the bracket is held securely.



Assemble the PORD™ device in the following way: Slide the Horizontal Bar through the Box Bracket with its curved portion facing the fracture table.
This curved section is designed to accept the C-arm of the Image Intensifier.




The Screw Jack of the Limb Support should be seated completely within the Housing of the Horizontal bar with the Nut turned so that it lies just beneath the Radiolucent Ledge.



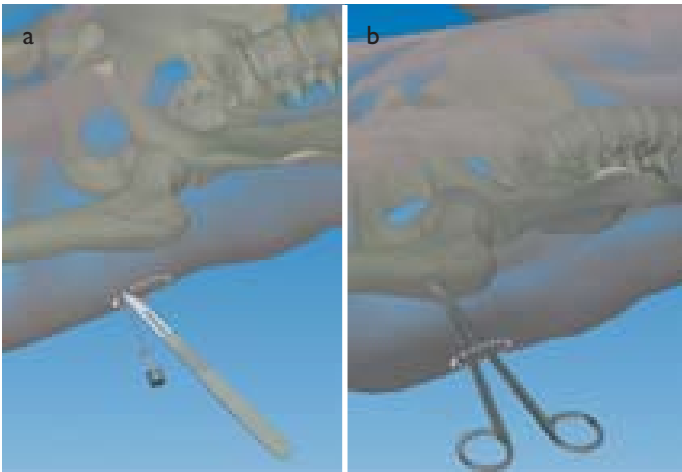
The Limb Support is positioned beneath that portion of the fracture which requires elevating.

The correct position of the support is confirmed on the AP view (the shadow of the support can be seen). Again using the lateral view, the limb support is raised by turning the nut (a) until exact posterior reduction has been achieved. The position of the Support is now maintained by tightening the Lug Screw on the housing (b). There is tendency for the Limb Support to rotate when its position is being adjusted, due to the conical cross-section of the thigh. It should therefore be held firmly during this procedure, and while tightening the Lug Screw. The PORD device will now remain in position throughout surgery. It can be draped and therefore does not require sterilization. It may be cleaned following surgery using a detergent solution and dried thoroughly.




Operative Procedure


The patient is prepped and draped in the normal manner. The Aiming Guide is now placed on the anterior surface of the thigh, to coincide with the position of the arrow on the plastic template (usually at the upper border of the lesser trochanter). An 18 gauge spinal needle is now inserted into the thigh immediately beneath the Aiming Guide, at the level of the center of the femoral shaft while palpating the anterior and posterior shaft border. Correct central positioning of the needle must be confirmed with a lateral image on the Image Intensifier and any adjustments in its position made at this stage.




While the needle is in position, using a No.10 scalpel blade, a 2 cm longitudinal skin incision proximal to the needle is now made. This incision should pass through the skin and fascia only, but not through the underlying soft tissues. The deep tissues are now separated by blunt dissection down to the bone surface using Metzenbaum scissors.



Take the introducer (191000) (a) and align it with the plate. The Butterfly screw (192000) (b) is now passed through the cylinder at the end of the Introducer (191000), and screwed into the hole in the blunt end (head) of the plate, ensuring that the body of the Introducer is parallel to the plate. This should be a “no-touch” technique. Initial connection is performed while the plate is still in the sterilization box, with final tightening following its removal.



The plate is inserted into the incision at right angles to the shaft of the femur (a). The vastus lateralis muscle is now split, using the chisel end of the plate, which is used to identify the anterior and posterior surfaces of the femur (b). If some soft tissue remains on the femoral shaft, a scalpel blade is used to dissect down to the bone.




With its chisel end over the center of the femoral shaft (a), the plate is now turned so that its long axis is essentially parallel to the femoral shaft (b) with the chisel end directed slightly anteriorly to take account of the anterior bowing of the bone. Using the chisel end as a blade, the plate is now advanced along the bone using small antero-posterior movements (c), in a plane of cleavage **between** the vastus lateralis muscle and the periosteum, which is preserved. Note that the plate must be deep under the muscle (d).




At this point correct positioning of the plate is confirmed with an AP view on the Image Intensifier, using the plastic template over the screen. **Correct AP position: The plate is in contact with and exactly parallel to the long axis of the femur, and when introduced, the distal (first) femoral neck screw will lie 2-3 mm above the calcar (= calcar notch line).** Corrections and adjustments can be made at this point to ensure that the desired position of the plate is obtained. A lateral image is of no value at this stage, since as yet, there is no reference point.



The second incision is now made. The scalpel is inserted through the middle hole of the introducer down to the skin, and a mark made on the skin. The scalpel is removed and used to make an incision, 2 cm in length, extending from the level of the distal margin of the middle shaft screw hole to the proximal margin of the proximal hole of the introducer. As before, this incision passes through skin and fascia only. The Metzenbaum scissors are again used for blunt dissection of the tissues down to the plate.



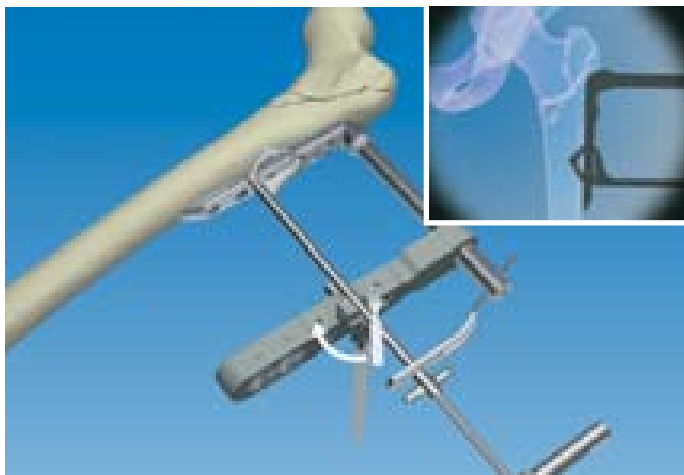The Metzenbaum scissors with blades closed are now brought to the anterior surface of the femoral shaft and moved from side to side to separate the tissues from the bone in preparation for insertion of the bone hook. Particular attention must be paid to this procedure to ensure easy insertion of the bone hook!



The bone hook adaptor (202000) is now inserted through the middle vertical hole of the introducer and secured in place by tightening its knurled knob.



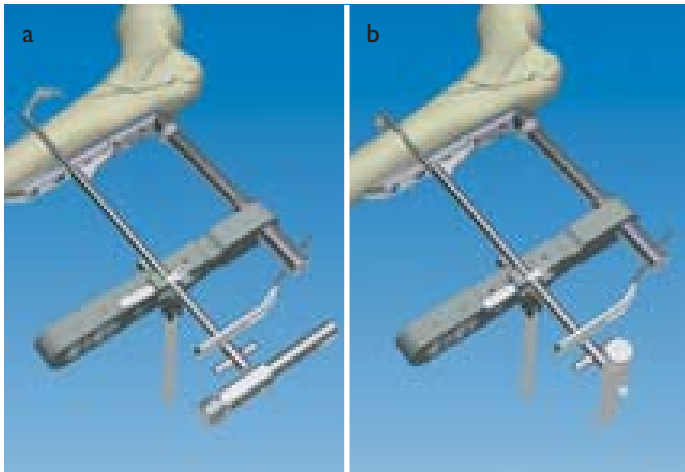
The bone hook (207000) has two jaws, a distal (bone) jaw which is curved to accept the medial aspect of the femur, and a flat proximal (plate) jaw to accept the plate. The hook is inserted through the second, distal incision, with its jaws **closed**. It is introduced in the frontal plane at 45 degrees to the femoral shaft so that the short cutting front edge of the bone jaw will enter the incision first.



Once within the incision the bone hook is turned so that it is at 90 degrees to the shaft of the femur in the frontal plane, and advanced into the wound, keeping the handle (and therefore the jaws) parallel to the introducer. The bone hook is now locked to the bone hook adaptor in this position. The correct AP position of the plate is confirmed with image intensification at this stage to ensure that its position has not been disturbed. (**lock and look**).



The wing screw on the bone hook is now unscrewed fully. The outer handle of the bone hook can now be advanced with turning movements to push the distal (bone) jaw medially, anterior to the femoral shaft. It should be noted, however, that the outer handle can only engage the bone jaw shaft when both are in the same plane. This is an important feature of the device since it provides information on the exact orientation of the bone jaw within the wound.



The bone jaw **only** is now pushed medially (a) and turned downwards (b) through 90 degrees to grasp the femur firmly, keeping the jaw in contact with the bone throughout. This can be accomplished without the need for an X-ray.

Note: the orientation of the handle shows the position of the jaw.



The plate jaw handle is now withdrawn until the **M-line** just disappears within the bone hook adaptor.

This indicates that the plate jaw has cleared the plate; it is now rotated downwards through 90 degrees so that it can grasp it. Both bone hook handles are now stabilized with the long arm of the bone hook adaptor (a). The jaws of the bone hook are now slightly tightened with the wing screw.



The position of the plate is now checked under lateral image intensification. **If it is correct, the head of the plate will be in line with the femoral neck and the tail of the plate will lie along the femoral shaft.** If a lateral view indicates that correction is needed, this can be made by twisting movements of the head and tail of the plate (the bone hook pivots) or by pulling the plate posteriorly (the bone hook glides and maintains the AP position). Check the AP position.

When both the AP and lateral position of the plate is satisfactory, the jaws of the bone hook are finally tightened with the wing screw to clamp the plate firmly to the bone.



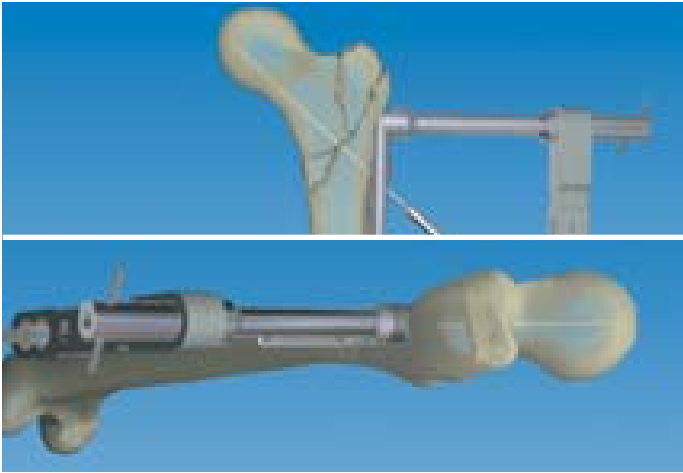
The main sleeve (195000) (a) and neck trocar (198000) (b) are now introduced through the most distal **oblique** hole of the introducer. This process is facilitated using the skin retractor (c) provided. The main sleeve is now locked into position with a bolt (d) inserted through the introducer. The trocar is withdrawn.



The first neck sleeve (196000) is identified by a single circumferential line around the head. It is inserted into the main sleeve and screwed into the plate. Any difficulty in achieving this may be due to soft tissue interposition, in which case the neck sleeve should be removed and the neck trocar reinserted and turned around to clear a path to the plate. The first neck sleeve is then reintroduced.

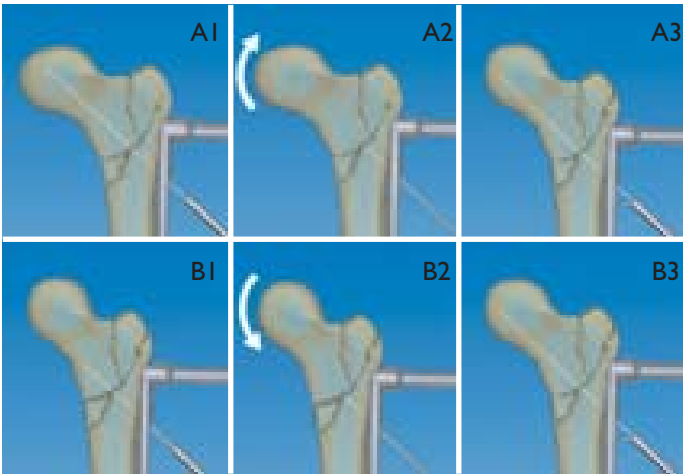


The main guide (189000Q) is now inserted into the first sleeve and drilled into the bone.



The position of the main guide is now monitored with AP and lateral views on the image intensifier. The AP view should show that it lies 2-3 mm above the calcar; the lateral should show that it lies within the middle third of the femoral neck. The main guide is then further advanced to a point approximately 3-5 mm from the articular surface.

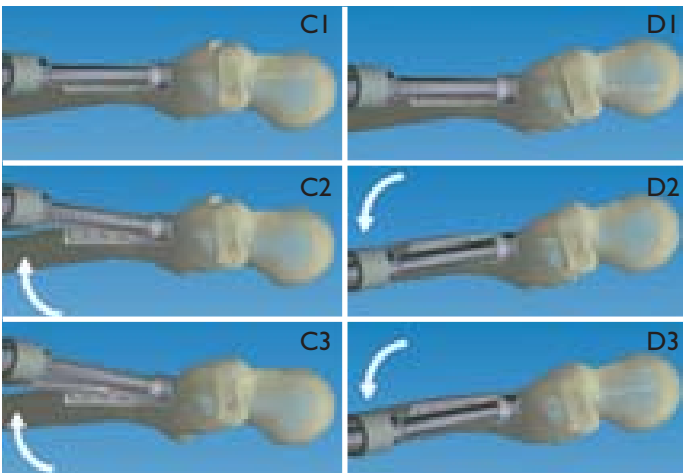
If any adjustment in the AP position is needed, the main guide can be withdrawn to a point just distal to the fracture line, and fracture table traction reduced or increased slightly (adding more varus or valgus) so that when reinserted, the main guide will adopt the correct position. This is an acceptable procedure where minor adjustments are required; if more major adjustments are needed, the plate may need to be moved up or down.



Important Guidelines

Fig A (AP view): Fracture is reduced in excessive varus; A1: Main Guide misplaced because of excessive varus; A2: Main Guide withdrawn distal to the fracture line and fracture table traction increased to correct the position; A3: Main Guide advanced again and now in the correct position.


Fig B (AP view): Fracture is reduced in excessive valgus; B1: Main Guide misplaced because of excessive valgus; B2: Main Guide withdrawn distal to the fracture line and fracture table traction reduced to correct the position; B3: Main Guide advanced again and now in the correct position.



Corrections in the lateral view can be made by moving the introducer up or down, bringing the main guide more anteriorly or more posteriorly as required.

Fig C (lateral view): C1: Main Guide is too anterior (although the plate head is in the correct position); C2: Main Guide is withdrawn distal to the fracture line and the introducer lifted; C3: Keeping the introducer lifted, the Main Guide is advanced again and is now in the correct position.

Fig D (lateral view): D1: Main Guide is too posterior; D2: Main Guide is withdrawn distal to the fracture line and the introducer lowered; D3: Keeping the introducer lowered, the Main Guide is advanced again and is now in the correct position.



Once the position of the Main Guide is correct on both AP and lateral views, the butterfly pin (193000Q) is inserted into the butterfly screw and drilled into the bone, all the way to the stop (a). This provides two point fixation of the plate to the femoral shaft.


With a very unstable fracture, additional stabilization may be provided by means of a fixation wire which is inserted through one of the accessory holes (b) in the introducer for a distance of 2-3 mm into the acetabulum. **This must be done under lateral image intensification.**



The length of main guide remaining outside, between its shoulder and the first neck sleeve, is a measure of the length of the neck screw required. This can be measured as shown, using the gauge (199000) with its square edge adjacent to the head of the first neck sleeve, and the oblique edge against the shoulder. The space over which the projecting portion of the main guide lies is marked with the length of screw required.




The main guide and first neck sleeve are now removed, and the second neck sleeve (197000) (identified by two circumferential lines around the head) introduced into the main sleeve and screwed to the plate.



The 7 mm drill bit (186000Q) is now inserted into the second neck sleeve and drilled up to its stop. The direction of drilling should follow the corrected position of the Main Guide. This should be monitored under lateral image intensification. The 7 mm drill bit and the second neck sleeve are now withdrawn.




The 9.3 mm drill bit (187000Q) is now inserted into the main sleeve and drilled to its stop (a). Care should be taken to ensure that the direction of drilling follows the path taken by the main guide. **If necessary, this may require the introducer to be raised or lowered slightly.** Ideally, drilling with the 7 mm and 9.3 mm drill bits should be performed under **lateral** image intensification. This will enable any corrections needed to centralize the drill to be made during the procedure.




The correct length neck screw is now attached to the Neck Screwdriver (184000). This instrument has:


1. An inner shaft (a) activated by **Grip 3**. This has a threaded end which engages the neck screw head.
2. An outer shaft (b) activated by **Grip 1**, which screws the outer barrel of the neck screw to the plate.
3. A middle shaft (c) activated by **Grip 2**. This shaft has a hexagonal end for screwing the neck screw into the bone.
4. A Nut, for compression of the fracture.
5. Two Buttons D and E to release and separate the handle for cleaning.




If the neck screws are correctly loaded in their dispenser the hexagonal recess in each will be at the level of the head of the screw barrel, ready for attachment to the Screwdriver. The nut “N” on the Screwdriver is turned until it is touching grip 2. This ensures that the hexagonal end of the Screwdriver is extended to its limit. The Screwdriver is now held vertically and its hexagonal end engaged in the hexagonal recess of the screw. Grip 3 is now pushed down and turned clockwise, applying gentle pressure while turning, to engage the threaded recess in the screw head.




Grip 1 is now slid forward until the teeth of the Screwdriver are seated in the cutouts (a) of the screw barrel thread. The teeth are locked in position by turning the nut “N” down to grip 1, keeping them aligned with the cutouts while doing so. **Care should be taken not to overtighten as this may disturb the alignment.**



The selected neck screw, mounted on the Screwdriver, is introduced into the main sleeve. Grip 1 is turned until the thread at the base of the screw barrel is completely screwed into the plate. When the line marked “L” on the Screwdriver shaft reaches the head of the main sleeve, this indicates that the threads of the screw barrel are entering the plate.




To advance the shaft of the screw into the femoral neck and head, nut “N” is turned counterclockwise until it meets grip 2. Under image intensification, grip 2 is now turned until the neck screw is positioned in the subchondral bone of the femoral head.



To exert a backward force on the screw to compress the fracture, nut “N” is now turned clockwise until it reaches grip 1. Further turning of nut “N” will compress the fracture. This should be done with the shaft trocar or, preferable with two fingers, under image intensification to ensure that the screw threads remain in place and do not tear the fragile trabeculae of the femoral head during the procedure. The neck screw can now be disengaged from the Screwdriver by turning grip 3 counterclockwise until an audible click is heard.



The impactor (200000) is now introduced through the main sleeve until it engages the barrel of the neck screw (a slight click is audible). A light hammer is used to minimally deform the thread in the plate. This will prevent the possibility of any backing out of the neck screw barrel during the cyclic loading produced on walking. The main sleeve and impactor are now removed.



The shaft sleeve (203000) and shaft trocar (204000Q) are now inserted through either the proximal or distal vertical hole of the introducer using the small skin retractor to assist entry into the incision.

The shaft sleeve is locked into position with a bolt (194000) inserted through the introducer, and the shaft trocar withdrawn.




Note that the shaft trocar has three additional functions:


1. A triangular hole for attachment to the shaft Screwdriver if manual application of the shaft screws is desired.
2. A cylindrical protrusion to assist in turning the grips of the neck Screwdriver.
3. A short Screwdriver for the neck screw barrel.



The 3.2 mm step drill bit is now used to predrill the bone.



The depth gauge (205000) is used to measure the length of bone screw required. It is introduced through the predrilled track and withdrawn until its hook engages the outer medial surface of the femur. The number which is now adjacent to the edge of the shaft sleeve head corresponds to the length of shaft screw required.



The correct length shaft screw is now attached to the shaft Screwdriver (185000Q) using gentle pressure. Note that the end of this Screwdriver is spring-loaded to grip the screw firmly for insertion or removal.



A power tool is normally used for insertion of the shaft screws. In this case insertion should be performed in stages, while listening carefully to the sound of the instrument to avoid stripping the thread in the bone. Where manual insertion is preferred, the triangular recess in the head of the shaft trocar is fitted over the end of the shaft Screwdriver. In osteoporotic bone it is recommended that the shaft screws are inserted manually.




The bone hook is now removed by simply reversing the steps used for its insertion.

The butterfly pin **must** now be removed.

The remaining two shaft screws are now inserted as described above, followed by the second (proximal) neck screw.

This neck screw is also inserted using the main guide in order to measure the length of screw required. Following screw introduction, the barrel is impacted to minimally deform the thread in the plate as before.

The introducer is now unlocked (butterfly screw) and removed.



The wound is now irrigated, and a suction drain left in situ for twenty four hours. The subcutaneous tissues and skin are closed in the normal manner and a full length elastic bandage or stocking applied to the lower extremity.

Post-operatively, full weightbearing may be allowed immediately, initially with a walking frame and subsequently with crutches.

Orthofix wishes to thank

Dr. Y. Gotfried, MD, MS

**for his invaluable help
in the preparation of this manual**

Your Distributor is:

www.orthofix.com



ORTHOFIX - Wonersh House - The Guildway - Old Portsmouth Road
Guildford - Surrey GU3 1LR - England
Tel. 44 1483 468800 Fax 44 1483 468829